

Guidelines for the diagnosis and management of hereditary spherocytosis

P. H. B. Bolton-Maggs¹, R. F. Stevens^{2†}, N. J. Dodd³, G. Lamont⁴, P. Tittensor⁵ and M.-J. King⁶ on behalf of the General Haematology Task Force of the British Committee for Standards in Haematology

¹Manchester Royal Infirmary, Manchester, ²Royal Manchester Children's Hospital, Manchester, ³The Ipswich Hospital NHS Trust, Ipswich, ⁴Royal Liverpool Children's Hospital, Alder Hey, Liverpool, ⁵Patient Representative, and ⁶International Blood Group Reference Laboratory, Bristol, UK

Summary

Hereditary spherocytosis (HS) is a heterogeneous group of disorders with regard to clinical severity, protein defects and mode of inheritance. It is relatively common in Caucasian populations; most affected individuals have mild or only moderate haemolysis. There is usually a family history, and a typical clinical and laboratory picture so that the diagnosis is often easily made without additional laboratory tests. Atypical cases may require measurement of erythrocyte membrane proteins to clarify the nature of the membrane disorder and in the absence of a family history, occasionally molecular genetic analysis will help to determine whether inheritance is recessive or non-dominant. It is particularly important to rule out stomatocytosis where splenectomy is contraindicated because of the thrombotic risk. Mild HS can be managed without folate supplements and does not require splenectomy. Moderately and severely affected individuals are likely to benefit from splenectomy, which should be performed after the age of 6 years and with appropriate counselling about the infection risk. In all cases careful dialogue between doctor, patient and the family is essential. Laparoscopic surgery, when performed by experienced surgeons, can result in a shorter hospital stay and less pain.

Keywords: spherocytosis, hereditary, splenectomy, child, erythrocyte membrane.

Hereditary spherocytosis (HS) was described in 1871 and the first recorded splenectomy was performed soon after. It is the commonest cause of inherited chronic haemolysis in Northern Europe and North America with a quoted incidence of 1 in 5000 births (Morton *et al*, 1962). However, studies of osmotic

fragility in blood donors suggest the existence of extremely mild or subclinical forms (Godal & Heisto, 1981; Eber *et al*, 1992), raising the prevalence of HS to 1 in 2000. HS has also been found in other ethnic groups (in Africa, Algeria, Tunisia, Egypt, Japan, North India and Brazil). There are only rare cases reported in the black population. In the last 15 years significant progress has been made in the understanding of the biochemical and molecular genetic basis of HS.

This guideline addresses several practical aspects:

- 1 Diagnosis
 - a. Which individuals should be screened for HS?
 - b. Which are the best diagnostic tests?
 - c. When is it necessary to measure membrane proteins?
 - d. What is the role of molecular genetic analysis?
- 2 Management
 - a. Does every child and adult with HS need folate supplementation?
 - b. What are the indications, timing and method of splenectomy?
 - c. What are the risks associated with splenectomy in HS? What advice should be given with regard to postsplenectomy antibiotic prophylaxis and what is the necessity and frequency of booster vaccinations?
 - d. How should gallstones be managed?

The definitions of the types of evidence and the grading recommendations used in this guideline are listed in Appendix.

Search strategy

In addition to personal archives and consultation of standard textbooks (together with relevant cited references therein), the writing group searched Medline and Embase to identify relevant literature including meta-analyses (none found), reviews and original papers in any language, using the following key words and combinations of them: hereditary spherocytosis; red cell membrane; spectrin, ankyrin, band 3, spherocytes; haemolysis; folate; folic acid; splenectomy; splenectomy in haematological

Correspondence: BCSH Secretary, British Society for Haematology, 100 White Lion Street, London, N1 9PF, UK.

E-mail: jules@b-s-h.org.uk

†RF Stevens sadly died prior to the final revisions of these guidelines.

conditions, cholecystectomy; cholecystostomy; laparoscopic; gallstones; pneumococcal; vaccination; penicillin prophylaxis, postsplenectomy sepsis, non-operative approaches to gall stones. Only the abstracts were read of papers published in languages other than English.

The biochemical basis of HS

The clinical expression of HS is relatively uniform within a given family, but the disease severity varies considerably between the different families.

Organization of red cell cytoskeleton

The abnormal morphology and shorter lifespan of the red cells in HS are attributable to a deficiency or dysfunction of one of the constituents of the red cell cytoskeleton (Delaunay *et al*, 1996; Tse & Lux, 1999) whose role is to maintain the shape, deformability and elasticity of the red cell (Fig 1).

The red cell cytoskeleton is a spectrin-based network of proteins located immediately on the cytoplasmic side of the membrane lipid bilayer. Each spectrin protein (alpha and beta) consists mainly of repeating units (106 amino acids long) that fold into triple helices. The paired alpha/beta spectrin heterodimers form head-to-head tetramers while the other end of the spectrin heterodimer is associated with protein 4.1 and actin (Fig 1). The vertical attachment of the spectrin network to the lipid bilayer involves two transmembrane proteins, band 3 and glycophorin C. Band 3, existing as dimer and tetramers *in situ* in red cells, has multiple protein-binding sites. It can interact with ankyrin,

which binds to beta-spectrin. In addition to binding protein 4.1 on its cytoplasmic N-terminal domain, band 3 interacts with protein 4.2 to provide additional stability for the cytoskeleton (Rybicki *et al*, 1996). Glycophorin C interacts with protein p55 and protein 4.1, which in turn binds to beta spectrin. Thus a deficiency of, or a dysfunction in, any one of these membrane components within the vertical attachment can weaken or destabilize the cytoskeleton, resulting in abnormal red cell morphology and a shorter lifespan for the affected red cells in the circulation.

Biochemical abnormalities associated with HS

The abnormal red cell morphology (resulting in shortened cell survival) is due to a deficiency of, or a dysfunction in, spectrin, ankyrin, band 3 and/or protein 4.2 (reviews Delaunay *et al*, 1996; Tse & Lux, 1999). Severe haemolytic anaemia is often associated with a greater reduction of the affected membrane protein(s). There is an apparent correlation between clinical and protein phenotypes (Miraglia del Giudice *et al*, 1994). HS red cells are found to have single or combined protein deficiencies as determined by sodium dodecyl sulphate-polyacrylamide gel electrophoresis (SDS-PAGE). An analysis of 174 HS patients from 123 families in the UK uncovered a larger proportion of spectrin-deficient probands whose parents are apparently normal when compared with other protein deficiencies. Autosomal dominant HS is often found to have primary mutations in the genes of ankyrin, band 3 or β spectrin. Primary mutations in these three genes can lead to a secondary protein deficiency detected by SDS-PAGE (Table I).

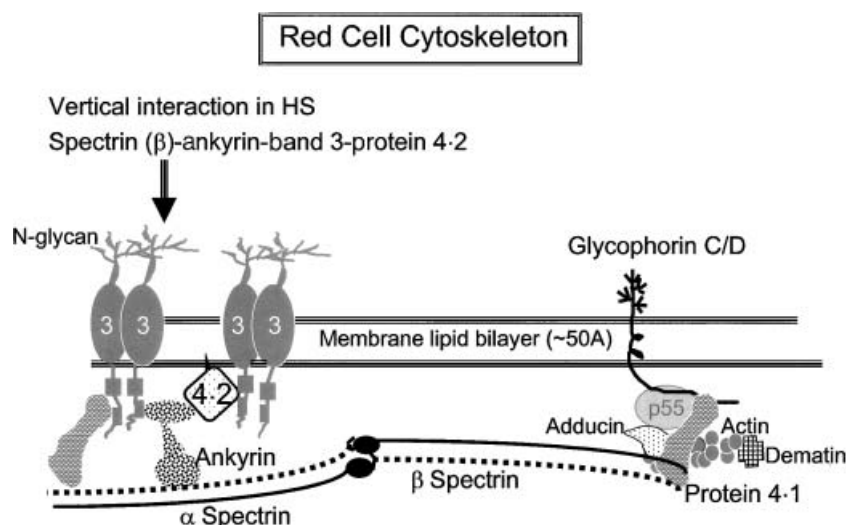


Fig 1. Schematic presentation of the structural organization of red cell cytoskeleton (Bolton-Maggs, 2004). β Spectrin is the key component in that it pairs with α spectrin to form a heterodimer, and it has binding sites for ankyrin and protein 4.1. The common protein defects are associated with spectrin (α and/or β), ankyrin, band 3 protein and protein 4.2. Although protein 4.1 abnormality and spectrin mutations are usually associated with hereditary elliptocytosis, a subset of hereditary spherocytosis was found to have β spectrin mutant proteins that had defective interaction with protein 4.1 (Goodman *et al*, 1982; Wolfe *et al*, 1982). This figure is a preprint from an article accepted for publication by Archives of Disease in Childhood, and may not, save under the fair dealing of the provision of the Copyright Designs and Patents Act (1988), be reproduced without the consent of the BMJ publishing group.

Table I. Probable primary causes for producing the observed (or secondary) membrane protein defects.

Observed protein deficiency by SDS-PAGE	Primary defect in protein or gene
Partial spectrin and protein 4·2 deficiency	Missing one haploid set of <i>ANK1</i>
Partial ankyrin and spectrin deficiency	Ankyrin gene mutation(s)
Partial spectrin deficiency	A variety of molecular defects
Marked deficiency of spectrin (parents are normal)	Severe ndHS due to low expression allele inherited in trans to a second Sp allele (i.e. HS)
Partial band 3 deficiency	Band 3 mRNA instability
Partial protein 4·2 deficiency	Band 3 gene mutations resulting in loss of protein 4·2 binding site

Table II. Membrane molecules associated with erythrocyte cytoskeleton.

Protein	Band on gel	Mr (kD)	Gene	Chromosomal location	Number of exons
α Spectrin	1	240	<i>SPTA1</i>	1q22-q23	52
β Spectrin	2	220	<i>SPTB</i>	14q23-q24·1	32
Ankyrin	2·1	210	<i>ANK1</i>	8p11·2	42
Band 3 (AE1)	3	90–100	<i>AE1</i> (<i>SLC4A1</i>)	17q21-q22	20
Protein 4·1	4·1	80	<i>EPB41</i>	1p36·2-p34	≥ 22
Protein 4·2	4·2	72	<i>EPB42</i>	15q15-q21	13
Glycophorin C	GPC	32	<i>GYPC</i>	2q14-q21	4

Molecular genetics of HS

The genes encoding membrane proteins of the red cell cytoskeleton and their respective chromosomal locations are known (Table II). Further information can be accessed from websites such as <http://www.kidscancer.net/membrane/> and the Human Gene Mutation Database at <http://www.hgmd.org> (Stenson *et al*, 2003).

Very different molecular mechanisms can generate the same membrane protein deficiency in HS. Most of the reported protein gene mutations in HS are 'private' or sporadic occurrences, i.e. they are specific to one family or found in a few families from different countries. Knowledge of the gene mutation does not influence the clinical management of the patient but analysis of mutant protein gene in family studies can clarify one of the following conditions.

- 1 To identify the primary gene defect. Family study will yield information on whether the abnormal protein in the proband is encoded by a mutant candidate gene or due to a secondary event resulting from a mutation in a different protein gene (examples shown in Table I).
- 2 To confirm recessive or non-dominant (r/nd)-HS when both parents are apparently normal. Different genetic backgrounds can give rise to r/nd-HS, which have been found in association with α spectrin, ankyrin and β spectrin genes. Recent analysis of nd-HS in an Italian population

(Miraglia del Giudice *et al*, 2001) has shown that the occurrence of *de novo* non-dominant mutations in HS patients with normal parents is six times more common than recessive mutations (level III evidence). The distribution of the nd-HS clinical phenotypes nearly overlapped with the group of dominant HS.

The Sp α ^{LEPRA} allele (LEPRA: Low Expression PRAGue) is prevalent among nd-HS (Boivin *et al*, 1993; Wichterle *et al*, 1996; Dhermy *et al*, 2000). This allele remains silent when inherited by a normal individual. However, mutations in the spectrin gene (*SPTA1*), both homozygous and compound heterozygous (co-inherited with a pathogenic HS allele), result in severe HS with very low spectrin levels in the red cells.

De novo mutations are mostly found in recessive HS associated with the ankyrin gene (*ANK1*) (Eber *et al*, 1996) and β spectrin (*SPTB*) (Miraglia del Giudice *et al*, 1998). The transmission of these ankyrin mutations to subsequent generations occurs in a dominant manner. A recurrent frameshift mutation, Ankyrin Florianópolis, has been found in three unrelated probands with severe dominant HS from different genetic backgrounds (Gallagher *et al*, 2000).

In the case of band 3 gene defect, additive effects of two unequally expressed AE1 mutant alleles can aggravate the clinical features of an affected individual (Alloisio *et al*, 1996, 1997; Bracher *et al*, 2001). The mutations associated with band 3 are heterogeneous with no apparent founder effect.

Clinical features and diagnosis

Hereditary spherocytosis is a heterogeneous group of disorders with regard to clinical severity, protein defects and mode of inheritance. The clinical severity of HS varies from symptom-free carrier to severe haemolysis. Mild HS can be difficult to identify because individuals may have a normal haemoglobin and bilirubin. The presence of spherocytes and a reticulocytosis will support the diagnosis. If there are no spherocytes seen on the film, no abnormalities in the red cell indices and the reticulocyte count is normal, a 'carrier' state cannot be excluded, but the individual is unlikely to have any clinical

sequelae. Occasionally mild HS can be exacerbated by illnesses that cause splenomegaly, such as infectious mononucleosis (Gehlbach & Cooper, 1970).

Age at diagnosis

Although the diagnosis of HS is often made in childhood and young adult life, it may be diagnosed at any time, even in the seventh to ninth decades of life (Friedman *et al*, 1988). It is perhaps surprising that the diagnosis of HS is not always considered as a cause of gallstones and splenomegaly in adult life, and that even in recent years there may be a considerable interval between the onset of symptoms and diagnosis (Reinhart *et al*, 1994). Asymptomatic HS may also be uncovered (usually in childhood) after an aplastic crisis, particularly when associated with Parvovirus B19 (Summerfield & Wyatt, 1985; Lefrere *et al*, 1986; Cohen *et al*, 1991), or influenza infection (Jensson *et al*, 1977). Hydrops fetalis or stillbirth can occur when a fetus has inherited defects in membrane proteins from both parents (Whitfield *et al*, 1991; Gallagher *et al*, 1995). Very mild HS may be first detected during investigation of asymptomatic relatives of a known case or during pregnancy (Kohler *et al*, 1960; Pajor *et al*, 1993).

Clinical features

The diagnosis of HS is generally straightforward. The patient, usually a child, has a variable degree of anaemia, jaundice and splenomegaly. It is important to ask for a family history of jaundice and/or splenectomy, as families may not realize that the cause involves their red blood cells.

Neonatal jaundice is common and may be severe enough to require exchange transfusion, but is not clearly related to the subsequent severity of HS. The mechanism for this is not clearly understood. It should be noted that the diagnosis of HS in neonates may be difficult (Schroter & Kahsnitz, 1983). The film appearances may not be typical and the osmotic fragility test is unreliable. As potential parents, adult patients need to be advised of the risk of neonatal jaundice, as occasionally exchange transfusion has been required for severe hyperbilir-

ubinaemia. There may be an interval of several days before bilirubin reaches its peak, so infants born to known parents with HS should be carefully monitored over several days.

Co-inheritance of other haematological disorders, such as beta thalassaemia trait or SC disease, can lead to confusion in the diagnosis and variable clinical effects (Gallagher *et al*, 1998). Iron, folate or vitamin B12 deficiencies can mask the laboratory features. Obstructive jaundice alters the lipid composition of the red cell membrane, masking the film appearances and reducing the haemolysis.

Family history

Most cases (75%) will have a family history of HS. In clear-cut cases [typical history and physical findings, spherocytes on the blood film with a reticulocytosis and negative direct antiglobulin test (DAT)] there is no indication to perform further special laboratory tests to arrive at the diagnosis. In the absence of a family history the most important differential diagnosis is autoimmune haemolysis. This is rare in children, but can follow a viral infection and is usually transient. Usually (but not always) this can be excluded by a negative DAT (see below). Other membrane abnormalities must be considered if the morphology is atypical, and in these, further investigations may be required (see below).

Consideration of individual clinical features

Anaemia

The severity of anaemia is closely associated with the severity of haemolysis and spleen size. Many individuals have compensated haemolysis and have a normal haemoglobin level with a reticulocytosis. During pregnancy some non-splenectomized HS patients may present with sufficiently severe anaemia to warrant blood transfusion.

Symptoms of HS may appear in the perinatal period: jaundice is common in the first 2 d of life. Some neonates with HS may be transfusion-dependent due to their inability to mount an adequate erythropoietic response in the first year of

Table III. Classification of spherocytosis and indications for splenectomy (modified from Eber, S.W., Armbrust, R. & Schroter, W. Variable clinical severity of hereditary spherocytosis: relation to erythrocytic spectrin concentration, osmotic fragility and autohemolysis. *Journal of Pediatrics*, 177, 409–411 (copyright 1990, with permission from Elsevier).

Classification	Trait	Mild	Moderate	Severe
Haemoglobin (g/dl)	Normal	11–15	8–12	6–8
Reticulocyte count %	Normal (<3%)	3–6	>6	>10
Bilirubin ($\mu\text{mol/l}$)	<17	17–34	>34	>51
Spectrin* per erythrocyte (% of normal)	100	80–100	50–80	40–60
Splenectomy	Not required	Usually not necessary during childhood and adolescence	Necessary during school age before puberty	Necessary – delay until 6 years if possible

*Data on spectrin content are provided for interest; it is not necessary to measure this.

life (Delhommeau *et al*, 2000) (level III evidence). Continued transfusion dependence is unusual and it is important to avoid repeated transfusion where possible. Recent evidence suggests that erythropoietin may be of benefit in reducing or avoiding transfusion, and can usually be stopped by the age of 9 months (Tchernia *et al*, 2000). Many older children with Hb levels of 5–6 g/dl do not require transfusion. Children who require one or two transfusions early in life frequently become transfusion independent.

Splenomegaly

Most children and adults with HS have mild to moderate enlargement of the spleen, but other than assisting in the diagnosis, this is of little clinical significance. The size of the spleen *per se* is not an indication for splenectomy. There is no evidence from the literature that splenic rupture is commoner than in the normal population.

Associated medical conditions may rarely be associated with HS, particularly various neuromuscular conditions (Gallagher *et al*, 1998), psychomotor retardation associated with abnormalities in chromosome 8 (also the location of the ankyrin gene) (Chilcote *et al*, 1987; Cohen *et al*, 1991) and eye disease manifested by angioid streaks (McLane *et al*, 1984).

Disease severity

Hereditary spherocytosis patients are usefully clinically classified as 'mild', 'moderate' or 'severe' (for criteria see Table III), and this correlates with the spectrin content detected in the red cell membranes – more severe clinical disease being associated with lower spectrin content. Furthermore, it predicts the clinical behaviour and the need for and response to splenectomy (Agre *et al*, 1986; Eber *et al*, 1990) (Table III – level III evidence). Clinical manifestations of the disorder in a majority are abrogated by splenectomy. However, those with severe HS, most notably where the red cells have $\leq 50\%$ spectrin content, remain anaemic postsplenectomy (Agre *et al*, 1986), and some of them may need blood transfusion during an infection. Recently it has been shown that the nature of the membrane defect (whether predominantly spectrin/ankyrin, or band 3) influences the response to splenectomy (Reliene *et al*, 2002). The assessment of severity should be made when the patient is well, preferably with a number of baseline tests over a period of time, rather than relying on the results and picture which first drew the patient to medical attention when perhaps unwell and decompensated, leading to a false assessment of the severity of HS.

Recommendation

Patients with HS should be graded by their severity of disease (baseline Hb, reticulocyte count, jaundice, level of activity). This predicts clinical course and the need for splenectomy. See Table III (level III evidence, grade B recommendation).

Table IV. Diagnostic parameters for hereditary spherocytosis.

Parameter	Features
Clinical features	Splenomegaly almost always
Laboratory red cell indices	(\downarrow Hb, \downarrow MCV, \uparrow MCHC, $\uparrow\%$ hyperdense cells, \uparrow RDW, \uparrow reticulocyte count)
Blood film	Abnormal morphology – spherocytes
Direct antiglobulin test	Negative
Evidence of haemolysis	Raised bilirubin; reticulocytosis

MCV, mean cell volume; MCHC, mean cell Hb concentration; RDW, red cell distribution width.

Laboratory investigation

The laboratory diagnosis is usually straightforward and is based upon a combination of clinical history, family history, physical examination (splenomegaly, jaundice) and laboratory data (full blood count, especially red cell indices and morphology, and reticulocyte count) (Table IV). Other causes of haemolytic anaemia should be excluded, particularly autoimmune haemolytic anaemia caused by warm (IgG) or cold (IgM) autoantibodies, i.e. positive DAT. Autoimmune haemolysis (AIHA) can usually be excluded by a negative DAT. AIHA is uncommon in children and would not show the strong family history commonly present in HS. There can be difficulty in interpreting DAT-negative AIHA in an individual with no family history, particularly an adult. In some cases the density of attached autoantibody may be too low for detection by DAT. This may be resolved by flow cytometric assessment of red cell Ig density (Kerr *et al*, 2000). Polyspecific DAT reagents may also fail to detect some autoantibodies, particularly IgA autoantibodies, as anti-IgA is not usually incorporated into the reagent. Application of specific anti G, A, M and complement DAT reagents may resolve some cases (Bardill *et al*, 2003).

In neonates haemolysis caused by irregular maternal antibodies must be excluded, at least by a negative DAT. The diagnosis of HS may be difficult in the neonatal period. If the baby is well, testing can be postponed until the child is at least 6 months of age or older when the morphology may be less confusing. The eosin-5-maleimide (EMA) binding dye test (see below) will be positive irrespective of morphology. Other membrane abnormalities must be considered if the morphology is atypical, and in these, further investigations may be required.

Red cell morphology

The appearance of spherocytes in HS is attributed to a spleen-mediated loss of microvesicles from discoidal red cells. In addition to spherocytes and/or microspherocytes, HS red cells with diverse morphology have also been noted. Acanthocytes or spiculated red cells (8–15%) were found in patients with β spectrin gene mutations (Wolfe *et al*, 1982; Hassoun *et al*,

Table V. Elevated automated red cell parameters in the prediction of hereditary spherocytosis and its severity.

Parameters	Remarks	Reference
Combined MCHC and RDW (or HDW)	Significantly higher in HS	Pati <i>et al</i> (1989)‡, Michaels <i>et al</i> (1997)§
Combined % hyperdense* cells and RDW	Excellent diagnostic efficacy and indication of HS severity	Pilar Ricard & Gilanz (1996)‡
% Microcytes†	The best indicator of HS severity	Cynober <i>et al</i> (1996)‡
Combined MCHC and % hyperdense cells	A discriminating feature of the HS phenotype	Cynober <i>et al</i> (1996)‡

HDW, Hb distribution width.

*Hyperdense cells are also present in Hb SC disease, Hb CC disease and xerocytosis.

†Physiological microcytosis occurs in children (Dallman & Siimes, 1979).

‡Dual angle laser light scattering haematology analyser.

§Electronic aperture impedance haematology analyser.

1997), and pincered (or mushroom-shaped) cells have been found in unsplenectomized HS with band 3 deficiency (Jarolim *et al*, 1996; Dhermy *et al*, 1997). In a case of severe haemolytic HS with a combined deficiency of spectrin and ankyrin, red cells with an irregular contour (resembling red cells of hereditary pyropokilocytosis) were seen (Palek & Sahr, 1992). Ovalostomatocytosis is a consistent feature for Japanese HS patients whose red cells have a protein 4.2 deficiency resulting from a protein 4.2 gene mutation in nt 142GCT → ACT (Yawata *et al*, 1994).

It is important to differentiate HS from hereditary stomatocytosis and related disorders with abnormal permeability of sodium and potassium ions. These disorders are rare; the morphology may not be typical, particularly where films are not freshly made. Such families have been labelled as 'atypical' HS. Splenectomy is not effective and is associated with a high risk of thrombosis (Stewart *et al*, 1996; Stewart & Turner, 1999; level III evidence).

An artefact showing 'macrocytosis' on a blood film can be produced as a result of cold storage of blood samples from patients with cryohydrocytosis, which is a variant form of hereditary stomatocytosis (Haines *et al*, 2001). This blood picture may inadvertently suggest a diagnosis of 'atypical HS'. Although hereditary stomatocytosis and related disorders with abnormal permeability of sodium and potassium ions are rare, their differentiation from HS is essential because HS red cells have also been found to have abnormal cation membrane permeability, unrelated to a specific membrane protein defect (De Franceschi *et al*, 1997). Moreover, splenectomy is not effective for the dehydrated and overhydrated forms of hereditary stomatocytosis, and is associated with a high risk of thrombosis (Stewart *et al*, 1996; Stewart & Turner, 1999).

Red cell indices

Haematology analysers using the principle of flow cytometry (i.e. dual angle laser light scattering method) produce a more accurate determination of red cell volume (MCV) and haemoglobin concentration (MCHC) than those blood cell analysers using the principle of electrical aperture impedance (Mohandas *et al*, 1986). These automated red cell parameters

can be used to predict or identify HS with a typical clinical presentation during the routine full blood count (Tables IV and V) without requiring additional laboratory tests (such as osmotic fragility or the EMA binding test) to confirm the diagnosis. These parameters are more pronounced in splenectomized than in non-splenectomized HS patients.

Additional tests for the diagnosis of HS

Additional testing for confirmation of HS is indicated when the diagnostic criteria are not met, and other causes of haemolysis have been excluded. For instance, the film appearances are atypical, there is no clear pattern of inheritance, or the proband has an on-going mild haemolytic process, albeit with an apparently normal full blood count result. The diagnosis may be particularly difficult in the neonatal period because spherocytes are commonly seen in neonatal blood films (Schroter & Kahsnitz, 1983).

Screening tests. All the laboratory tests currently in use can detect typical HS (Table VI). The acid glycerol lysis test has a higher detection rate in asymptomatic relatives of known affected individuals than the osmotic fragility test. The drawback of both tests is an apparent lack of specificity under certain circumstances. In addition to detecting HS, they give positive results with a wide spectrum of clinical disorders or red cells in which abnormalities are unrelated to structural protein defects (Table VI). For instance, the osmotic fragility test cannot differentiate between causes of spherocytosis (immune *versus* non-immune).

A normal osmotic fragility result does not exclude the diagnosis of HS and may occur in 10–20% of cases of HS (Dacie *et al*, 1991). The test may also be normal in the presence of iron deficiency, obstructive jaundice, and in the recovery phase from an aplastic crisis when the reticulocyte count is increased (Korones & Pearson, 1989). Cell dehydration occurring in the spherocytes of a patient with HS can be one of the causes of normal osmotic fragility results for non-splenectomized HS patients (Cynober *et al*, 1996). Furthermore, a positive osmotic fragility result can be obtained in patients with hereditary elliptocytosis (HE) and haemolysis.

Table VI. Screening tests for the diagnosis of hereditary spherocytosis.

Test	Method	Evaluation (sensitivity, specificity, precautions)
Osmotic fragility (OF) test* (Parpart <i>et al</i> , 1947)	Heparinized whole blood (50 µl) per tube. Measure absorbance at 540 nm for fresh blood and after 24 h incubation. Plot a graph of % haemolysis versus NaCl concentration	Affected by elevated reticulocyte count: increased OF in 66% of non-splenectomized HS patients. Also increased OF found in immune-mediated and other haemolytic conditions
Acidified glycerol lysis test (AGLT)† (Zanella <i>et al</i> , 1980) The Pink test (Bucx <i>et al</i> , 1988) is a modified AGLT	EDTA (20 µl) whole blood per tube. Measure the time taken for absorbance of red cell suspension at 625 nm in glycerol to fall to half of its original value before glycerol addition (AGLT ₅₀)	Also detects autoimmune haemolytic anaemia, hereditary persistence of fetal haemoglobin, pyruvate kinase deficiency, severe glucose-6-phosphate dehydrogenase deficiency, pregnant women (one-third), chronic renal failure on dialysis (some), and myelodysplastic syndrome. Reagent preparation: special attention to pH and osmolality
Osmotic gradient ektacytometry‡ (Clark <i>et al</i> , 1983)	A laser diffraction viscometer that measures red cell deformability at constant shear stress as a continuous function of suspending osmolality (hypotonic to hypertonic)	Distinct deformability curves for red cells from patients with HS, hereditary elliptocytosis, hereditary pyropoikilocytosis, stomatocytosis and sickle disease (Mohandas <i>et al</i> , 1980)
Hypertonic cryohaemolysis test (Streichman & Gescheidt, 1998)	Packed red cells (50 µl) per tube. % cryohaemolysis at 540 nm after transfer of red cells from 37°C to 0°C for 10 min	Positive results for HS, some CDAIL and Melanesian elliptocytosis
Eosin-5-maleimide (EMA) binding§ (King <i>et al</i> , 2000)	Packed red cells (5 µl; EDTA sample) per tube. Reduced fluorescence (green) intensity of EMA-labelled red cells by flow cytometry	Distinct histograms for red cells of HS (sensitivity of 92.7% for HS and a specificity of 99.1%) and HPP. Reduced fluorescence with CDAIL, cryohydrocytosis, SAO. Reagent: solution of EMA (light-sensitive) must be stored at -20°C (max. 3 months)

*The shift of OF curve reflects the red cell response to hypotonic medium due to reduced cell volume and surface area.

†The red cell lipid composition regulates the membrane permeability to glycerol. The added glycerol slows down the rate of water entry into the red cells. This allows the measurement of time taken for cell lysis to occur.

‡There is no ektacytometer in the UK. Measurement of red cell membrane resistance to fragmentation under shear stress.

§EMA binds to band 3, Rh blood group proteins, Rh glycoprotein and CD47 on membrane molecules in intact red cells (King *et al*, 2004).

The cryohaemolysis test, the osmotic gradient ektacytometry and the EMA binding test have a higher predictive value in the diagnosis of HS because there have been no reports of positive results in immune or non-membrane-associated disorders. However, these tests are not specific, and can also detect red cells with rare membrane disorders, such as aberrant band 3 proteins [e.g. CDAIL, Southeast Asian ovalocytosis (SAO)], a change in intracellular viscosity (e.g. sickle cells), and temperature-sensitive monovalent cation transport (e.g. cryohydrocytosis) (Table VI). In mild or atypical cases, difficulty in interpretation is likely to occur with results that fall between normal and typical HS reference ranges. Therefore, ektacytometry has an advantage in that results are plotted as a deformability curve, which has a distinct shape for each type of abnormal red cells tested (Mohandas *et al*, 1980). In EMA binding by flow cytometry, hereditary pyropoikilocytosis (HPP, MCV < 60 fl) and HE can be differentiated from HS, based on the graded reduction in fluorescence intensity for HPP (the lowest) < HS < HE ≤ normal controls (King *et al*, 2000, 2003). Although similar fluorescence readings to the red cells of HS are obtained with some rare red cell disorders – CDAIL, SAO (also known as

Melanesian elliptocytosis) and cryohydrocytosis – these can be distinguished from HS on the basis of their distinct clinical features (Table VII). Other atypical cases with spherocytosis can produce anomalous histograms, which are identified by overlaying the test histogram with those of normal and HS controls (King *et al*, 2003). Normal fluorescence results are obtained for individuals presenting a reticulocytosis or an autoimmune haemolytic anaemia (King *et al*, 2000).

In conclusion, when selecting an appropriate test for determining mild or atypical HS condition in a patient, the sensitivity and specificity of the test for HS, the complexity of the protocol, and the total cost of instrument(s) and its maintenance should be taken into consideration. As HS is a structural defect of the red cell cytoskeleton, the test result is expected to give a clear distinction between a membrane-associated and a non-membrane-related red cell disorder.

SDS-PAGE. Identifying a deficiency in a membrane protein associated with erythrocyte cytoskeleton confirms the diagnosis of HS. Quantitation of membrane proteins by SDS-PAGE is, however, not necessary for the majority of HS

Table VII. Features of South-East Asian ovalocytosis (SAO), congenital dyserythropoietic anaemia type II (CDAII), and hereditary stomatocytosis (HSt.) and related disorders.

Disorder	Mode of transmission	Clinical features	Red cell indices and morphology	Laboratory test
SAO*	Autosomal dominant	Asymptomatic of any haemolysis	Rigid and hyperstable. 25% or more ovalocytes. Some SAO cells show a 'slit' in the cells	(a) SDS-PAGE detects a slower migrating Band 3 Memphis (Lys ⁵⁶ → Glu) protein (b) Detect deletion of 27 nts in band 3 gene
CDAII (HEMPAS)	Autosomal recessive	Mild and intermittent jaundice, and splenomegaly. Hepatomegaly and gallstones are less frequent. Anaemia, liver cirrhosis and secondary tissue siderosis	Bi- and multinucleated erythroblasts (usually 15–30%). Mild to moderate Hb level, normal to mild elevated MCV. Low reticulocyte count	A more compact and faster migrating band 3 (due to incomplete N-glycosylation) by SDS-PAGE. Confirmation of CDA by electron microscopy of bone marrow sample
Overhydrated HSt. (hydrocytosis)	Dominant	Frequency 1 in 1 million births. Indistinguishable from HS (atypical HS)	Stomatocytes (some have 30%) decreased MCHC, macrocytosis	Stomatatin absent (band 7·2 in SDS-PAGE); intracellular [Na ⁺] > 60 mmol/l red cells
Dehydrated HSt. (xerocytosis)	Dominant	Frequency 1 in 10 000; heterogeneous: combined with pseudohyperkalaemia and/or perinatal oedema	Lack deformability: some stomatocytes and target cells; increased MCHC	Normal stomatin. Measure intracellular [Na ⁺] and [K ⁺]
Familial pseudo-hyperkalaemia	Dominant	Non-haemolytic (normal haematology without jaundice)	Normal	Normal or near normal intracellular Na ⁺ , net loss of [K ⁺] when stored at room temperature; apparently normal cation fluxes at 37°C
Cryohydrocytosis	Dominant	Rare, mild stomatocytic haemolytic state with hyperbilirubinaemia, gallstones	Red cell lysis when stored at 4°C (increased intracellular Na ⁺)	Measure intracellular [Na ⁺] and [K ⁺]

*Also known as Melanesian hereditary elliptocytosis. Found mainly in Malaysia, Indonesia, Papua New Guinea, the Philippines. Occasionally in South African (White), one Afro-American family.

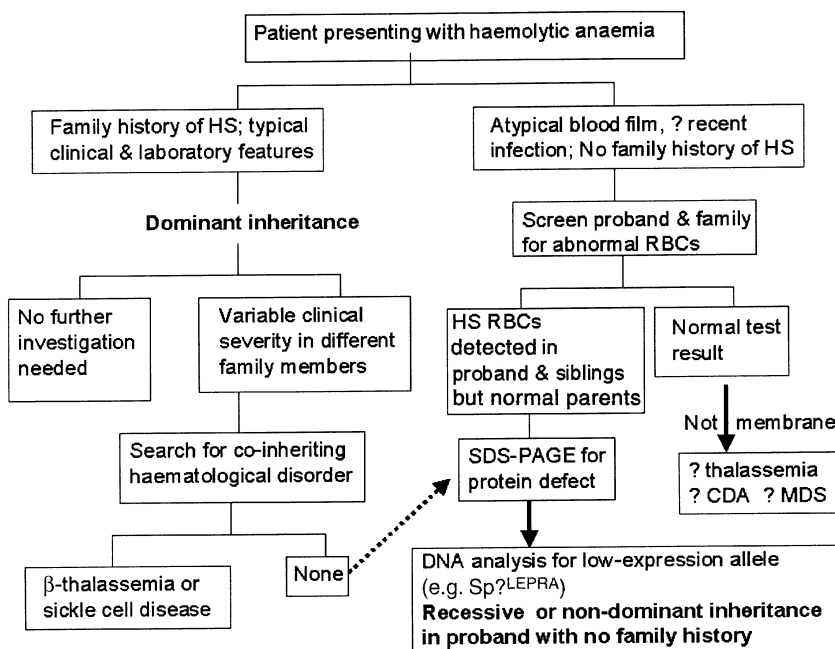


Fig 2. Flow chart for the diagnosis of hereditary spherocytosis (modified from Iolascon *et al* 1998).

cases because a definitive diagnosis can be made on the basis of red cell indices, clinical/family history and positive result from a screening test. Nevertheless, SDS-PAGE can be useful in HS cases where the index member has a clinical condition inconsistent with that of the affected parent(s) and siblings (see *Biochemical abnormalities associated with HS*).

Information on genetic analysis. There are currently no facilities for the determination of molecular defects in the protein genes associated with HS in the UK.

The DNA-based methods in the diagnosis of common inherited diseases are applicable to the detection of erythrocyte membrane protein gene mutations. The rapid screening based on single-strand conformation polymorphism can be carried out to detect mutations in the coding region of cDNA of all the HS-associated genes. Linkage analysis has been successfully used in the search for candidate genes in dominant HS (Costa *et al*, 1990; Garbarz *et al*, 1996, 1998). Determination of the (AC)_n microsatellite-length polymorphism at the 3' end of the ankyrin gene provides an indicator for ankyrin abnormality (e.g. an absence of reticulocyte ankyrin mRNA) (Jarolim *et al*, 1995; Eber *et al*, 1996).

Recommendations

A suggested diagnostic pathway is shown in Fig 2 – modified from Iolascon *et al* (1998).

- 1 Newly diagnosed patients with a family history of HS, typical clinical features (splenomegaly) and laboratory investigations (spherocytes, raised MCHC, increase in reticulocytes) do not require any additional tests (level III evidence, grade B recommendation).
- 2 If the diagnosis is equivocal, for example, where there are a few spherocytes on the film but no other laboratory, clinical or family evidence, a screening test with high predictive value for HS is helpful (level IV evidence, grade C recommendation). The recommended screening tests are the cryohaemolysis test and the EMA binding test (level IIa/III evidence, grade B recommendation). The high predictive value of both techniques for the diagnosis of HS can be improved further when the results are used in conjunction with clinical information and red cell indices. The availability of a flow cytometer may be the deciding factor for choosing the EMA binding method. In view of the probable inherent differences in flow cytometers, each laboratory must set up its own cut-off value for distinguishing between normal and HS red cells (mean \pm 2SD), and normal reference range (King *et al*, 2000) (level IIa evidence, grade B recommendation). Osmotic fragility may still be performed purely as a supportive investigation, but its limitations must be recognized. It should be possible for all laboratories to make arrangements for the EMA dye test to be provided by a collaborating service.

- 3 Confirmation of the diagnosis may be necessary in selected cases if the screening tests produce an equivocal or borderline result. Gel electrophoresis analysis of erythrocyte membranes is the method of choice (level III evidence, grade B recommendation). This technique is useful for determining the extent of membrane deficiency for the patient. The main drawback is a lack of sensitivity to very mild or asymptomatic 'carrier' HS. The use of SDS-PAGE is recommended:
 - a. When the clinical phenotype is more severe than predicted from the red cell morphology.
 - b. When the red cell morphology is more severe than predicted from parental blood films where one parent is known to have HS.
 - c. If the diagnosis is not clear prior to splenectomy, when a patient might have an abnormality in monovalent cation permeability. Where the morphology is typical there should be no doubt. In more subtle cases (when MCV > 100 fl) clarification may be essential (Delaunay *et al*, 1999). Splenectomy may not be appropriate for the clinical management of these patients (Stewart *et al*, 1996; Stewart & Turner, 1999) (level IIa evidence, grade B recommendation).
- 4 Diagnosis of HS does not require further investigation by molecular analysis of the affected genes (level III evidence, grade B recommendation).

Clinical management of individuals with HS: medical

Indications for folate therapy

Folate supplements have traditionally been prescribed to all individuals with chronic haemolysis. Is this required, particularly in mild cases of haemolysis? Megaloblastic anaemia has been reported in 11 cases of HS, including two children (level III evidence). Review of the literature led to the conclusion that the evidence 'although highly fragmentary, therefore suggests that folic acid deficiency has been responsible in the majority of cases' (Lindenbaum & Klipstein, 1963). Folate replacement is probably only required as a routine for children with severe haemolysis, (Rosenblatt & Hoffbrand, 1999) and in pregnancy, whatever the severity of the HS. Various regimens are suggested – 1 mg/d, 5 mg once a week, 100 µg/kg/d. The daily requirement in normal adults is only about 200 µg/d and, for children the World Health Organization (WHO) recommended intake is 3.3–3.6 µg/kg/d. Consideration should be given to the socio-economic environment of the child (folate deficiency is more likely to occur in association with poverty), and their diet, in addition to the severity of the HS, before committing a child to lifelong medication. Folates are wide-

spread in food, especially in fresh fruit and vegetables (which must not be overcooked). Breakfast cereals are also an important source in children aged 1–4 years. The National Diet and Nutrition Survey in the UK showed that at all ages the average daily intake in 1995 was well above the reference nutrient intake, being 143% for children over 4 years, and 184% in children under 4 years, suggesting that folate supplementation is unnecessary in mild HS.

Recommendation

Folate therapy is recommended in severe and moderate HS, but is probably not necessary in mild HS. (level III and IV evidence, grade C recommendation). A reasonable daily dose would be 2.5 mg/d up to the age of 5 years, and 5 mg/d thereafter.

Routine observation and frequency of blood tests

Children. Once a diagnosis of HS has been established a child should be regularly followed up; for most children (those with mild and moderate HS) an annual visit is sufficient once the baseline has been established, and in the absence of symptoms a blood count at every visit is unnecessary. If possible, the same team should see the child and parents at each annual visit. This is particularly important in the years leading up to the decision for or against splenectomy. At each visit, general health, growth, spleen size and exercise tolerance should be recorded. A locally written explanatory booklet should be provided. If this is not available the families should be given advice about sources of information about HS. It is important to provide information on parvovirus B19, as an aplastic crisis is potentially dangerous and is certainly the most frightening complication for most families. Children who are not receiving regular folate supplements may have their folate status checked to ensure levels are sufficient (see above). Ultrasound examination for biliary stones may be performed from the age of 5 years at convenient intervals – probably every 3–5 years is sufficient in the absence of symptoms. Severely affected children will require haematological supervision during intercurrent viral infections, when they may be decompensated. Children who are regularly transfused in the early years (a very small group) should receive genotyped leucodepleted blood in order to reduce the risk of reactions and alloimmunization. (level III and IV evidence, grade C recommendations).

Adults. The value of an annual visit in those with mild disease is debatable. The disruption to their lives outweighs any benefit. Providing the patient and general practitioner are

aware of the disorder it is unnecessarily disruptive to insist on regular review. There is however perhaps some benefit in regular annual review of those with moderate disease (and to monitor by ultrasound examination for the development of gallstones) or those who have had splenectomy, if only to discuss current views about postsplenectomy management (re-vaccination, antibiotic prophylaxis). It is also worth checking fasting iron status annually (transferrin saturation) in non-splenectomized cases. Chronic anaemia will enhance iron absorption, and co-inheritance of the haemochromatosis gene (C282Y) even in the heterozygous state can lead to severe iron overload. (grade C recommendations, based on level IV evidence.)

Clinical management of individuals with HS: surgery

This section will address the following questions:

- 1 In which patients is splenectomy indicated?
- 2 When should splenectomy be performed?
- 3 What approach to splenectomy should be used?
- 4 Should a concurrent cholecystectomy be performed?
- 5 Postsplenectomy thrombosis – what is the risk?

In which patients is splenectomy indicated?

Splenectomy is very effective in reducing haemolysis, leading to a significant prolongation of the red cell lifespan, although not necessarily to normal (Chapman & McDonald, 1968; Baird *et al*, 1971) (level III evidence). The clinical manifestations and complications (anaemia and gallstones) are much reduced in severe HS and abolished in milder cases, but at the price of an increased risk of life-threatening sepsis from encapsulated organisms, particularly *Streptococcus pneumoniae*.

Patients should be selected for splenectomy on the basis of their clinical symptoms (Table III) and presence of complications such as gallstones, not simply on the basis of the diagnosis alone (level III evidence, grade B recommendation). Splenectomy should be performed in children with severe HS, considered in those who have moderate disease, and should probably not be performed in those with mild disease. A careful history is important in those with moderate to mild disease to establish if there is evidence suggesting reduced exercise tolerance; the metabolic burden of increased marrow turnover may be considerable. Where there is a family history, the benefit of splenectomy in other individuals may help to determine whether to proceed.

An analysis of decision-making for mild HS, based on the available literature and computer modelling, suggests that splenectomy is of no benefit in the absence of gallstones (Marchetti *et al*, 1998). Children or young adults with mild HS who also have gallstones are likely to benefit from

combined splenectomy and cholecystectomy in terms of life expectancy. However, this model assumed 100% compliance with penicillin prophylaxis, and if only 10% of splenectomized patients are non-compliant (which is likely) then splenectomy is considered too risky for patients with mild HS at any age. A difficult group are those with visible jaundice but no stones, and who want splenectomy for cosmetic reasons, but who have well compensated HS by other criteria. However, these children often have a significant reticulocytosis and splenectomy may be justified on the basis that they are therefore likely to have symptomatic gallstones later in life.

Infection risks and their management. The risk of postsplenectomy sepsis is not completely eliminated by the currently recommended preoperative vaccinations and postsplenectomy antibiotic prophylaxis (BCSH, 1996; Davies *et al*, 2002). There are numerous studies documenting an increased mortality from sepsis; particularly notable was a study of more than 1400 children in the US (Eraklis & Filler, 1972) and an early UK study of more than 800 children demonstrating an age-related risk (Walker, 1976), which was highest in the younger children, <2 years of age, and early after splenectomy. A study of 456 children who had splenectomies in Denmark between 1969 and 1978 also demonstrated an incidence of pneumococcal bacteraemia and meningitis in the splenectomized children that was 284 times that of non-splenectomized children (Pedersen, 1983). Although the risk is maximal in young children and early after splenectomy, it persists for life (Ein *et al*, 1977; Evans, 1985; Holdsworth *et al*, 1991; Deodhar *et al*, 1993; Eber *et al*, 1999). The risk has been reduced by deferring splenectomy until a child is over 6 years of age, together with vaccination and antibiotic prophylaxis (Konradsen & Henrichsen, 1991). The small but definite remaining risk of sepsis must be clearly explained to the parents and the child, and the indications for splenectomy must be clear. Many adults who themselves may have had splenectomy in the past may be unaware of the risks. Conversely, adults who have received vaccinations and antibiotics may perceive that there is no risk of infection and also need appropriate education.

Presplenectomy vaccination and postsplenectomy follow-up. Patients should be vaccinated according to national guidelines (BCSH, 1996; Davies *et al*, 2002). Fatal infection may occur with a serotype not covered by the vaccine, or there may not have been an adequate response to some of the 23 serotypes in the face of an adequate global response in terms of functional antibody testing. Although repeat pneumococcal vaccination is recommended at 5-year intervals, there is no clear evidence in the literature. Some data exist demonstrating that antibody levels may fall off quite quickly (Spickett *et al*, 1999). Good longitudinal follow-up studies of splenectomized or hyposplenic patients to look at some of these issues are

badly needed (Reid, 1994). The recent update of the BCSH guidelines (Davies *et al*, 2002) did not recommend any changes to the current policy with the introduction of new pneumococcal vaccines, but this needs regular review as more evidence is gathered.

Antibiotic prophylaxis. Penicillin prophylaxis is recommended for life postoperatively, but there is little published evidence of efficacy (Reid, 1994). The guidelines indicate that antibiotic prophylaxis should be for life, although the evidence base for this is not strong (BCSH, 1996; Davies *et al*, 2002). Urgent medical attention (even hospital admission) should be sought in the event of a febrile illness – however it is difficult to translate this into a practical reality with children who are often febrile with minor viral illnesses.

Despite recommendations for vaccination and antibiotic prophylaxis (BCSH, 1996), ignorance persists in affected families, and compliance with antibiotic advice is poor (Waghorn & Mayon-White, 1997; Keenan *et al*, 1999; Spickett *et al*, 1999). Although preventive measures are very successful (Konradsen & Henrichsen, 1991) it is clear that they do not completely eliminate the risk. The risk of infection remains highest in the youngest patients but was reported to be reduced by 47%, and the mortality by 88% in one study (Jugenburg *et al*, 1999). Fatal pneumococcal infections have occurred despite both vaccination and compliance with penicillin prophylaxis (Deodhar *et al*, 1993; Spickett *et al*, 1999). A recent study references at least 19 severe postsplenectomy infections, six fatal, in vaccinated patients (Eber *et al*, 1999) (level III evidence).

Recommendations

- 1 Patients and parents should be informed about the lifelong small risk of overwhelming sepsis after splenectomy, and provided with a splenectomy card.
- 2 National guidelines for management should be followed (BCSH, 1996; Davies *et al*, 2002). The need for reimmunization and its frequency are unclear as are the optimal duration of postsplenectomy antibiotic prophylaxis and choice of drug.

When should splenectomy be performed?

No published evidence of the optimum timing for any type of resection exists. All the major texts essentially state that the timing is one of clinical judgement and that it depends on the severity of the patient's symptoms as judged by the effects of anaemia, or the need for transfusion, or symptoms related to cholelithiasis. More severe clinical disease (transfusion-dependent) will benefit from early splenectomy but the risks must be balanced.

Recommendations on timing of surgery in relation to postsplenectomy sepsis

The risk of serious sepsis is highest in young children and in the first few years postsplenectomy (level III evidence). Splenectomy should therefore be carried out as late as possible, preferably after the age of 6 years; before this age it is only warranted in very severe transfusion-dependent disease and even so, should not be carried out before the age of 3 years (Gallagher *et al*, 1998) (grade B recommendation). It is convenient to perform surgery before children enter secondary education and before puberty places an additional burden on erythropoiesis, i.e. before the age of 12 years. The risk of serious sepsis persists for life (level III evidence).

What approach should be used?

Laparotomy. The traditional approach to splenectomy has been total, by laparotomy, through either an upper midline incision or more usually a left sub-costal approach. The spleen has been removed in its entirety and a careful search made for any splenunculi (accessory splenic tissue) in the assumption that any splenic tissue left behind may lead to a recurrence of symptomatic anaemia. There are no studies that have quantified this risk, although it has been reported (Mackenzie *et al*, 1962).

Laparoscopic splenectomy. The traditional approaches are being challenged by the advent of laparoscopy. There are no published randomized trials comparing laparoscopic splenectomy to traditional approaches, although there are a number of small reviews outlining experience with laparoscopic splenectomy, either on its own (Smith *et al*, 1994; Rescorla *et al*, 2002; Tanoue *et al*, 2002) or in combination with cholecystectomy (Caprotti *et al*, 1999). There are several other studies that detail the outcomes of cholecystectomy alone (Rescorla & Grosfeld, 1992; Holcomb, 1998) (level III evidence). Each of these is a descriptive study and compares the outcomes of an institution's experience against either historical data from the same institution or reported results from other institutions. These latter results are often from a different time period. Published results demonstrate that the laparoscopic approach is both feasible and safe (Danielson *et al*, 2000), although there is no good evidence of benefit over the more traditional approach. Laparoscopic splenectomy is more difficult in the presence of significant splenic enlargement (Bagdasarian *et al*, 2000) so that a preoperative assessment of splenic size by ultrasound is recommended (Esposito *et al*, 1998). There is a potential for shorter hospital stay, fewer problems with wound infections, improved pain relief (Curran *et al*, 1998), although in practice none of this has yet been demonstrated by randomized

controlled trials. In general, it is a feasible approach from surgeons who have the necessary equipment, training and experience to carry out these procedures safely. The spleen is caught in a specimen bag introduced through the port site, and fragmented inside this so that the contents can be removed through the port. Cholecystectomy may be performed at the same time (Farah *et al*, 1997). Whether the traditional or laparoscopic route is chosen will be determined by local practice and expertise.

Partial splenectomy. Concern over the possible consequences of sepsis has led some groups to investigate whether it is necessary to remove the whole spleen to control haemolysis. Partial splenectomy can improve transfusion-dependent infants with very severe HS while preserving some splenic function as protection against sepsis (level III evidence). A number of reports have been published (Tchernia *et al*, 1993, 1997; Bader-Meunier *et al*, 2001). Forty patients were followed for 1–14 years and it was shown that the majority remained symptom-free, although three patients subsequently required total splenectomy for further symptomatic anaemia (Bader-Meunier *et al*, 2001), but only 17 of 40 patients had completed at least 5 years follow up and a further five were lost to follow-up. It is too early to determine whether others will need total splenectomy. The phagocytic function of the spleen was sustained (demonstrated by technetium 99m scans) and there were no reports of serious infection. It was not clear whether the ability of the spleen to participate in humoral defence was maintained, thus these patients were recommended to continue with both immunizations and anti-bacterial prophylaxis. Another group have also reported favourable results in 16 children with HS followed for up to 6 years after partial splenectomy (Rice *et al*, 2003). Both of these series are small, and have been followed for too short a time to determine whether this procedure reduces the risks of postsplenectomy sepsis. A further caution is that four of 18 patients developed new gallstones after subtotal splenectomy.

Should a concurrent cholecystectomy be performed?

In children with no evidence of cholelithiasis, there is no indication to remove the gall bladder at the time of splenectomy.

Symptoms of cholelithiasis remain a prime reason for carrying out a splenectomy in hereditary spherocytosis. Stones themselves are reported to be present in 21–63% of cases (Rutkow, 1981). Once the spleen is removed, individuals with HS do not develop pigment stones. In the absence of stones, splenectomy alone is sufficient. A recent review of 17 patients who had undergone splenectomy without cholecystectomy (gall stones excluded pre- or peri-operatively) under the age of 18 years demonstrated that none developed any evidence of cholelithiasis (clinical or sub clinical) over a mean follow-up of 15 years (Sandler *et al*, 1999).

A significant number of children with HS develop pigment stones in the first decade of life. The risk is increased in individuals who co-inherit Gilbert syndrome with HS – these individuals have a fivefold increased risk of developing gallstones (Miraglia del Giudice *et al*, 1999) (level III evidence). An Italian survey of 468 children with HS showed that 79 had gallstones, about half of them were diagnosed before the age of 11 years (level III evidence) (Pinto *et al*, 1995). A recent study of 103 unsplenectomized children has shown that the pigmented stones seen in haemolytic diseases are radio-opaque in 50%, but ultrasound has an accuracy of 96% (Miraglia del Giudice *et al*, 1999). Regular ultrasound examination of the biliary system from the age of about 5 years may identify individuals more likely to have troublesome symptoms later in life, and who may benefit from splenectomy prior to puberty. It is not clear whether adults with mild HS should be regularly screened by ultrasound for asymptomatic gallstones, particularly as it is not clear whether these should be removed. One study has shown chronic inflammatory changes in the gall bladder mucosa in individuals with asymptomatic stones (Csendes *et al*, 1998). However, there are no good longitudinal studies of the outcome in children with silent stones, if left alone. One study of 123 adults with silent stones (not relative to haemolytic conditions) found that only 15–20% developed symptoms over a prolonged follow-up (Gracie & Ransohoff, 1982). In both adults and children, regular follow-up should include assessment of possible symptoms (typical and atypical) suggestive of gall bladder disease. Individuals with symptomatic gallstones usually have a cholecystectomy at the same time as the splenectomy; however some surgeons prefer cholecystostomy (simple removal of stones, leaving the gall bladder) in young children, as the risk of stones is markedly reduced after splenectomy and there is evidence that cholecystectomy may lead to alterations in bile salt metabolism that predisposes to colon carcinoma later in life, but the evidence for this is controversial (Robertson *et al*, 1988).

There are no randomized controlled trials comparing different approaches to management but, in general, there is a consensus for removing the gall bladder in the presence of stones, if there have been symptoms of gall bladder disease (biliary colic, cholecystitis). The consensus is less clear about the appropriate action when stones are asymptomatic, and an incidental finding. Although some authors have suggested that all patients with stones, even the asymptomatic ones, should undergo cholecystectomy (Gotz *et al*, 1977), there is enough evidence to suggest that removal of stones may alone be sufficient after splenectomy. Robertson *et al* (1988) reported on the clinical and ultrasound follow-up of five children with HS who had cholecystostomy with stone removal at the time of splenectomy. In four of the cases there were no stones, but in one an asymptomatic stone was discovered. However, the follow-up period was short (1–2 years), and there have been no further reports of systematic follow-up of this cohort. In a study of 17 patients, Sandler *et al* (1999) identified that none

of their cohort of patients had shown either overt or sub-clinical gall bladder disease after a median follow-up of 18 years.

The surgical management of HS is thus largely founded on ‘custom and practice’ (level III and IV evidence) rather than the evidence of controlled trials. There are a number of questions that could be answered by well-designed observational studies, although to have any statistical meaning they would have to be multi-centred.

Recommendations

- 1 There is no evidence that one surgical approach is superior to another, and the choice of the laparoscopic route would be dependent on the availability of appropriately trained surgeons, and suitable equipment (level III evidence, grade B recommendation).
- 2 Partial splenectomy may be of benefit in very young children with severe disease, but it is likely that further surgery may need to be undertaken for either recurrence of haematological problems or symptomatic cholelithiasis (level IV evidence, grade C recommendation).
- 3 In children undergoing splenectomy for symptoms of cholelithiasis, the gall bladder should be removed. If stones are an incidental finding, a cholecystostomy may be sufficient, although follow-up to include ultrasound examination of the gall bladder will be necessary (level III evidence, grade B recommendation).
- 4 In children who require cholecystectomy for symptoms of gallstones, the spleen should always be removed as well, otherwise the risk of stones persists (level IV evidence, grade C recommendation).
- 5 When splenectomy is indicated, ideally it should be performed after the age of 6 years, but before puberty (level IV evidence, grade C recommendation).

What is the risk of late post splenectomy thrombosis?

Adults undergoing splenectomy should receive standard thromboprophylaxis where indicated. Splenectomy is usually followed by a reactive thrombocytosis that may be quite spectacular in children, with counts rising to more than $1000 \times 10^9/l$ (Hirsh & Dacie, 1966; Boxer *et al*, 1978; Coon *et al*, 1978). Current evidence suggests that the only individuals in whom there is an increased risk of late (i.e. not related to the surgery itself) thrombosis after splenectomy are those with myeloproliferative disorders (Gordon *et al*, 1978), or persisting anaemia with abnormal red blood cells (Hirsh & Dacie, 1966), and has been demonstrated for beta thalassaemia intermedia (Cappellini *et al*, 2000) and for forms of hereditary stomatocytosis (Delaunay *et al*, 1999). It is therefore vital to differentiate these membrane disorders from HS and to avoid splenectomy. Thrombotic events have anecdo-

tally been reported in patients with HS (Nikol *et al*, 1997; Hayag-Barin *et al*, 1998), but the frequency of inherited thrombotic risk factors is high enough (particularly factor V Leiden) in northern Europeans to suggest that these will occur by chance in association with HS. There is a suggestion that splenectomy may be associated with the subsequent development of pulmonary hypertension (Hoepfer *et al*, 1999). There is some recent evidence from animal models that there may be a risk of thrombosis related to the abnormal red cells in mice, with both HS and HE but this has not, as yet, been demonstrated in humans. Moreover, the thrombosis risk was abolished in these mice by the infusion of a small number of normal stem cells (Wandersee *et al*, 2001).

Recommendations

- 1 There is no indication for extended thrombosis prophylaxis after splenectomy in patients with HS. Adults should receive perioperative thromboprophylaxis in the usual way.
- 2 Splenectomy should be avoided in patients with some forms of hereditary stomatocytosis (level III evidence, grade B recommendations).

Other complications of HS and how they should be managed

Aplastic crisis

Hereditary spherocytosis that has previously been silent and undiagnosed may present typically in childhood with severe anaemia caused by parvovirus B19 infection (level III evidence). A sick febrile child is admitted with severe pallor, typically with a maculopapular rash on the cheeks ('slapped cheeks'), and often with diarrhoea and vomiting. Spherocytes on the blood film together with a firm moderately enlarged spleen are important clues; a mild accompanying thrombocytopenia and leucopenia are common and resolve with the infection. Anaemia may be severe, requiring blood transfusion. The aplastic crisis typically lasts 10–14 d. Parvovirus was recognized as the cause of aplastic crises in sickle cell disease in 1981–82, and is now known to be responsible for such episodes in any form of inherited haemolysis, including HS (Kelleher *et al*, 1983). It is helpful to confirm the diagnosis by documenting raised parvovirus IgM titres in the acute illness, because the parents can then be reassured that this is unlikely to happen again. Although other viral illnesses cause some decompensation in HS, the anaemia is very rarely as profound as that seen in acute parvovirus infections. Other family members with HS should be warned of the risk of catching this contagious viral infection.

Recommendations

Where clinical suspicion exists, it may be useful to serologically document infection with parvovirus B19. Some children with HS and parvovirus infection may require blood transfusion, but this should be kept to a minimum and be guided by clinical features, as complete recovery usually occurs within 10–14 d.

Rare complications

Growth failure may occur in severe cases, with marrow expansion and skeletal deformities. It is good practice to monitor height and weight serially. Leg ulcers have been described. Several unsplenectomized adult patients have been reported with extramedullary haemopoiesis, occasionally as the presenting feature of the disease. (Mulder *et al*, 1975; Petit & Estany, 1987; Bastion *et al*, 1990; Pulsoni *et al*, 1992; Xiros *et al*, 2001; Granjo *et al*, 2002; Sutton *et al*, 2003).

Conclusions

The methodology of diagnosis and clinical management of HS has changed over the past three decades. For many years, the diagnosis was usually followed almost automatically by splenectomy. The diagnosis was often all too evident, but difficult cases were rarely made easier by performing an osmotic fragility test. There then followed a period when splenectomy fell from favour because of the risks of postsplenectomy sepsis. However, presplenectomy immunization against *S. pneumoniae* (together with Hib and meningitis C vaccines if not already given as part of routine vaccination) together with prophylactic antibiotic therapy has reduced, although not totally eradicated, the risk. Postsplenectomy, there is no additional risk of thrombosis unless the patient has some other significant red cell disorder. Where indicated, thromboprophylaxis should be undertaken as for other abdominal surgery in adults.

The indications for splenectomy have become somewhat clearer and it is now possible to classify the majority of cases of HS into mild, moderate and severe. Splenectomy will be of benefit in all cases with severe and some cases with moderate HS, but is not usually necessary in mild cases. However, the final decision will rest on consultation between the family and clinician.

Research priorities

- 1 Further evaluation of the EMA binding test in the district general hospital setting is required.
- 2 The necessity for folate therapy needs to be reassessed in cases with mild haemolysis. Folate levels could be systematically measured with the full blood count at routine visits together with a record of folate therapy or absence of it.

- 3 The current Department of Health advice concerning postsplenectomy sepsis needs review in the light of emerging pneumococcal penicillin resistance and poor compliance with long-term penicillin therapy.
- 4 Further research is required to establish which pneumococcal vaccine should be used, and how often it needs repeating, and whether measurement of pneumococcal antibodies has any role.
- 5 Collaborative studies of the surgical management of HS that compare standard *versus* laparoscopic splenectomy would be helpful. In addition, further information is required from long-term studies of asymptomatic pigment gallstones – do they inevitably result in symptoms, or can patients be left alone, particularly in those in whom splenectomy would not otherwise be indicated? Is it safe to do a cholecystostomy alone? (Is there a role for national societies to collaborate here?) From a patient perspective, the research priorities centre on surgical intervention.
- 6 To determine whether or not abnormal cation efflux, detected in red cells of some HS patients, is a consistent indicator of increasing risk of thromboembolism post-splenectomy. As abnormal cation efflux has been reported in some HS patients, could there be a subset of patients who present overlapping features between HS and the red cell disorders associated with hereditary stomatocytosis?
- 7 An audit should be performed on all splenectomized patients to determine whether there is a higher incidence of thromboembolism in HS patients than in other groups of splenectomized individuals. It would be ideal to have a national splenectomy register to collect this and other information regarding postsplenectomy sepsis.

Disclaimer

While the advice and information in these guidelines is believed to be true and accurate at the time of going to press, neither the authors, the British Society for Haematology nor the publishers accept any legal responsibility for the content of these guidelines.

Source of funding

None.

Conflict of interest

None of the authors have received any funding from companies related to the disorder or its treatment.

References

Agre, P., Asimos, A., Casella, J.F. & McMillan, C. (1986) Inheritance pattern and clinical response to splenectomy as a reflection of ery-

throcyte spectrin deficiency in hereditary spherocytosis. *New England Journal of Medicine*, **315**, 1579–1583.

- Alloisio, N., Maillat, P., Carre, G., Texier, P., Vallier, A., Baklouti, F., Philippe, N. & Delaunay, J. (1996) Hereditary spherocytosis with band 3 deficiency. Association with a nonsense mutation of the band 3 gene (allele Lyon), and aggravation by a low-expression allele occurring in trans (allele Genas). *Blood*, **88**, 1062–1069.
- Alloisio, N., Texier, P., Vallier, A., Ribeiro, M.L., Morle, L., Bozon, M., Bursaux, E., Maillat, P., Goncalves, P., Tanner, M.J., Tamagnini, G. & Delaunay, J. (1997) Modulation of clinical expression and band 3 deficiency in hereditary spherocytosis. *Blood*, **90**, 414–420.
- Bader-Meunier, B., Gauthier, F., Archambaud, F., Cynober, T., Mielot, F., Dommergues, J.P., Warszawski, J., Mohandas, N. & Tchernia, G. (2001) Long-term evaluation of the beneficial effect of subtotal splenectomy for management of hereditary spherocytosis. *Blood*, **97**, 399–403.
- Bagdasarian, R.W., Bolton, J.S., Bowen, J.C., Fuhrman, G.M. & Richardson, W.S. (2000) Steep learning curve of laparoscopic splenectomy. *Journal of Laparoendoscopic and Advanced Surgical Techniques*, **10**, 319–323.
- Baird, R.N., Macpherson, A.I.S. & Richmond, J. (1971) Red-blood-cell survival after splenectomy in congenital spherocytosis. *Lancet*, **ii**, 1060–1061.
- Bardill, B., Mengis, C., Tschopp, M. & Wuillemin, W.A. (2003) Severe IgA-mediated auto-immune haemolytic anaemia in a 48-yr-old woman. *European Journal of Haematology*, **70**, 60–63.
- Bastion, Y., Coiffier, B., Felman, P., Assouline, D., Tigaud, J.D., Espinouse, D. & Bryon, P.A. (1990) Massive mediastinal extramedullary hematopoiesis in hereditary spherocytosis: a case report. *American Journal of Hematology*, **35**, 263–265.
- BCSH (1996) Guidelines for the prevention and treatment of infection in patients with an absent or dysfunctional spleen: Working Party of the British Committee for Standards in Haematology Clinical Haematology Task Force. *British Medical Journal*, **312**, 430–434.
- Boivin, P., Galand, C., Devaux, I., Lecomte, M.C., Garbarz, M. & Dhermy, D. (1993) Spectrin alpha IIa variant in dominant and non-dominant spherocytosis. *Human Genetics*, **92**, 153–156.
- Bolton-Maggs, P.H.B. (2004) Hereditary spherocytosis – new guidelines. *Archives of Disease in Childhood*, in press.
- Boxer, M.A., Braun, J. & Ellum, L. (1978) Thromboembolic risk of postsplenectomy thrombocytosis. *Archives of Surgery*, **113**, 808–809.
- Bracher, N.A., Lyons, C.A., Wessels, G., Mansvelt, E. & Coetzer, T.L. (2001) Band 3 Cape Town (E90K) causes severe hereditary spherocytosis in combination with band 3 Prague III. *British Journal of Haematology*, **113**, 689–693.
- Bux, M.J., Breed, W.P. & Hoffmann, J.J. (1988) Comparison of acidified glycerol lysis test, Pink test and osmotic fragility test in hereditary spherocytosis: effect of incubation. *European Journal of Haematology*, **40**, 227–231.
- Cappellini, M.D., Robbiolo, L., Bottasso, B.M., Coppola, R., Fiorelli, G. & Mannucci, A.P. (2000) Venous thromboembolism and hypercoagulability in splenectomized patients with thalassaemia intermedia. *British Journal of Haematology*, **111**, 467–473.
- Caprotti, R., Franciosi, C., Romano, F., Codecasa, G., Musco, F., Motta, M. & Uggeri, F. (1999) Combined laparoscopic splenectomy and cholecystectomy for the treatment of hereditary spherocytosis: is it safe and effective? *Surgical Laparoscopy Endoscopy and Percutaneous Techniques*, **9**, 203–206.

- Chapman, R.G. & McDonald, L.L. (1968) Red cell life span after splenectomy in hereditary spherocytosis. *Journal of Clinical Investigation*, **47**, 2263–2267.
- Chilcote, R.R., Le Beau, M.M., Dampier, C., Pergament, E., Verlinsky, Y., Mohandas, N., Frischer, H. & Rowley, J.D. (1987) Association of red cell spherocytosis with deletion of the short arm of chromosome 8. *Blood*, **69**, 156–159.
- Clark, M.R., Mohandas, N.M. & Shohet, S.B. (1983) Osmotic gradient ektacytometry: comprehensive characterization of the red cell volume and surface maintenance. *Blood*, **61**, 899–910.
- Cohen, H., Walker, H., Delhanty, J.D., Lucas, S.B. & Huehns, E.R. (1991) Congenital spherocytosis, B19 parvovirus infection and inherited interstitial deletion of the short arm of chromosome 8. *British Journal of Haematology*, **78**, 251–257.
- Coon, W.W., Penner, J., Clagett, P. & Eos, N. (1978) Deep venous thrombosis and postsplenectomy thrombocytosis. *Archives of Surgery*, **113**, 429–431.
- Costa, F.F., Agre, P., Watkins, P.C., Winkelmann, J.C., Tang, T.K., John, K.M., Lux, S.E. & Forget, B.G. (1990) Linkage of dominant hereditary spherocytosis to the gene for the erythrocyte membrane-skeleton protein ankyrin. *New England Journal of Medicine*, **323**, 1046–1050.
- Csendes, A., Smok, G., Burdiles, P., Diaz, J.-C., Maluenda, F. & Korn, O. (1998) Histological findings of gallbladder mucosa in 95 control subjects and 80 patients with asymptomatic gallstones. *Digestive Diseases and Sciences*, **43**, 931–934.
- Curran, T.J., Foley, M.I., Swanstrom, L.L. & Campbell, T.J. (1998) Laparoscopy improves outcomes for pediatric splenectomy. *Journal of Pediatric Surgery*, **33**, 1498–1500.
- Cynober, T., Mohandas, N. & Tchernia, G. (1996) Red cell abnormalities in hereditary spherocytosis: relevance to diagnosis and understanding of the variable expression of clinical severity. *Journal of Laboratory and Clinical Medicine*, **128**, 259–269.
- Dacie, J.V., Lewis, S.M. & Luzatto, L. (1991) Investigation of the hereditary haemolytic anaemias: membrane and enzyme abnormalities. In: *Practical Haematology* (ed. by J.V. Dacie & S.M. Lewis), pp. 195–225. Churchill Livingstone, Edinburgh.
- Dallman, P.R. & Siimes, M.A. (1979) Percentile curves for hemoglobin and red cell volume in infancy and childhood. *Journal of Pediatrics*, **94**, 26–31.
- Danielson, P.D., Shaul, D.B., Phillips, J.D., Stein, J.E. & Anderson, K.D. (2000) Technical advances in pediatric laparoscopy have had a beneficial impact on splenectomy. *Journal of Pediatric Surgery*, **35**, 1578–1581.
- Davies, J.M., Barnes, R. & Milligan, D. (2002) Update of guidelines for the prevention and treatment of infection in patients with an absent or dysfunctional spleen. *Clinical Medicine: Journal of the Royal College of Physicians of London*, **2**, 440–443.
- De Franceschi, L., Olivieri, O., Miraglia del Giudice, E., Perrotta, S., Sabato, V., Corrocher, R. & Iolascon, A. (1997) Membrane cation and anion transport activities in erythrocytes of hereditary spherocytosis: effects of different membrane protein defects. *American Journal of Hematology*, **55**, 121–128.
- Delaunay, J., Alloisio, N., Morle, L., Baklouti, F., Dalla Venezia, N., Maillet, P. & Wilmotte, R. (1996) Molecular genetics of hereditary elliptocytosis and hereditary spherocytosis. *Annals of Genetics*, **39**, 209–221.
- Delaunay, J., Stewart, G. & Iolascon, A. (1999) Hereditary dehydrated and overhydrated stomatocytosis: recent advances. *Current Opinion in Hematology*, **6**, 110–114.
- Delhommeau, F., Cynober, T., Schischmanoff, P.O., Rohrlich, P., Delaunay, J., Mohandas, N. & Tchernia, G. (2000) Natural history of hereditary spherocytosis during the first year of life. *Blood*, **95**, 393–397.
- Deodhar, H.A., Marshall, R.J. & Barnes, J.N. (1993) Increased risk of sepsis after splenectomy. *British Medical Journal*, **307**, 1408–1409.
- Dhermy, D., Galand, C., Bournier, O., Boulanger, L., Cynober, T., Schismanoff, P.O., Bursaux, E., Tchernia, G., Boivin, P. & Garbarz, M. (1997) Heterogenous band 3 deficiency in hereditary spherocytosis related to different band 3 gene defects [published erratum appears in *British Journal of Haematology* 1997, **99**, 474]. *British Journal of Haematology*, **98**, 32–40.
- Dhermy, D., Steen-Johnsen, J., Bournier, O., Hetet, G., Cynober, T., Tchernia, G. & Grandchamp, B. (2000) Coinheritance of two alpha-spectrin gene defects in a recessive spherocytosis family. *Clinical and Laboratory Haematology*, **22**, 329–336.
- Eber, S.W., Armbrust, R. & Schroter, W. (1990) Variable clinical severity of hereditary spherocytosis: relation to erythrocytic spectrin concentration, osmotic fragility and autohemolysis. *Journal of Pediatrics*, **117**, 409–411.
- Eber, S.W., Pekrun, A., Neufeldt, A. & Schroter, W. (1992) Prevalence of increased osmotic fragility of erythrocytes in German blood donors: screening using a modified glycerol lysis test. *Annals of Hematology*, **64**, 88–92.
- Eber, S.W., Gonzalez, J.M., Lux, M.L., Scarpa, A.L., Tse, W.T., Dornwell, M., Herbers, J., Kugler, W., Ozcan, R., Pekrun, A., Gallagher, P.G., Schroter, W., Forget, B.G. & Lux, S.E. (1996) Ankyrin-1 mutations are a major cause of dominant and recessive hereditary spherocytosis. *Nature Genetics*, **13**, 214–218.
- Eber, S.W., Langendorfer, C.M., Ditzig, M., Reinhardt, D., Stohr, G., Soldan, W., Schroter, W. & Tchernia, G. (1999) Frequency of very late fatal sepsis after splenectomy for hereditary spherocytosis: impact of insufficient antibody response to pneumococcal infection. *Annals of Hematology*, **78**, 524–528.
- Ein, S.H., Shandling, B., Simpson, J.S., Stephens, C.A., Bandi, S.K., Biggar, W.D. & Freedman, M.H. (1977) The morbidity and mortality of splenectomy in childhood. *Annals of Surgery*, **185**, 307–310.
- Eraklis, A.J. & Filler, R.M. (1972) Splenectomy in childhood: a review of 1413 cases. *Journal of Pediatric Surgery*, **7**, 382–388.
- Esposito, C., Corcione, F., Ascione, G., Garipoli, V., Di Pietto, F. & De Pasquale, M. (1998) Splenectomy in childhood. The laparoscopic approach. *Surgical Endoscopy*, **12**, 1445–1448.
- Evans, D.I. (1985) Postsplenectomy sepsis 10 years or more after operation. *Journal of Clinical Pathology*, **38**, 309–311.
- Farah, R.A., Rogers, Z.R., Thompson, W.R., Hicks, B.A., Guzzetta, P.C. & Buchanan, G.R. (1997) Comparison of laparoscopic and open splenectomy in children with hematologic disorders. *Journal of Pediatrics*, **131**, 41–46.
- Friedman, E.W., Williams, J.C. & Van Hook, L. (1988) Hereditary spherocytosis in the elderly. *American Journal of Medicine*, **84**, 513–516.
- Gallagher, P.G., Weed, S.A., Tse, W.T., Benoit, L., Morrow, J.S., Marchesi, S.L., Mohandas, N. & Forget, B.G. (1995) Recurrent fatal hydrops fetalis associated with a nucleotide substitution in the erythrocyte beta-spectrin gene. *Journal of Clinical Investigation*, **95**, 1174–1182.
- Gallagher, P., Forget, B. & Lux, S. (1998) Disorders of the erythrocyte membrane. In: *Nathan and Oski's Hematology of Infancy and*

- Childhood* (ed. by D. Nathan & S. Orkin), Vol. 1, pp. 544–664. Saunders, Philadelphia.
- Gallagher, P.G., Ferreira, J.D., Costa, F.F., Saad, S.T. & Forget, B.G. (2000) A recurrent frameshift mutation of the ankyrin gene associated with severe hereditary spherocytosis. *British Journal of Haematology*, **111**, 1190–1193.
- Garbarz, M., Bibas, D., Cynober, T., Galand, C., Bournier, O., Devaux, I., Tchernia, G. & Dhermy, D. (1996) Search for the candidate genes in dominant hereditary spherocytosis using linkage analysis. *Comptes Rendus de l'Academie des Sciences, Paris, Sciences de la Vie III*, **319**, 913–919.
- Garbarz, M., Galand, C., Bibas, D., Bournier, O., Devaux, I., Harousseau, J.L., Grandchamp, B. & Dhermy, D. (1998) A 5' splice region G→C mutation in exon 3 of the human beta-spectrin gene leads to decreased levels of beta-spectrin mRNA and is responsible for dominant hereditary spherocytosis (spectrin Guemene-Penfao). *British Journal of Haematology*, **100**, 90–98.
- Gehlbach, S.H. & Cooper, B.A. (1970) Haemolytic anaemia in infectious mononucleosis due to inapparent congenital spherocytosis. *Scandinavian Journal of Haematology*, **7**, 141–144.
- Godal, H.C. & Heisto, H. (1981) High prevalence of increased osmotic fragility of red blood cells among Norwegian blood donors. *Scandinavian Journal of Haematology*, **27**, 30–34.
- Goodman, S.R., Shiffer, K.A., Casoria, L.A. & Eyster, M.E. (1982) Identification of the molecular defect in the erythrocyte membrane skeleton of some kindreds with hereditary spherocytosis. *Blood*, **60**, 772–784.
- Gordon, D.H., Schaffner, D., Bennett, J.M. & Schwartz, S.I. (1978) Postsplenectomy thrombocytosis: its association with mesenteric, portal, and/or renal vein thrombosis in patients with myeloproliferative disorders. *Archives of Surgery*, **113**, 713–715.
- Gotz, M., Granditsch, G., Helmer, F., Howanietz, L. & Wagner, I.U. (1977) Cholelithiasis in children and adolescents (authors transl) *Wien Klin Wochenschr*, **89**, 686–690.
- Gracie, W.A. & Ransohoff, D.F. (1982) The natural history of silent gallstones: the innocent gallstone is not a myth. *New England Journal of Medicine*, **307**, 798–800.
- Granjo, E., Bauerle, R., Sampaio, R., Manata, P., Torres, N. & Quintanilha, A. (2002) Extramedullary hematopoiesis in hereditary spherocytosis deficient in ankyrin: a case report. *International Journal of Hematology*, **76**, 153–156.
- Haines, P.G., Jarvis, H.G., King, S., Noormohamed, F.H., Chetty, M.C., Fisher, J., Hill, P., Nicolaou, A. & Stewart, G.W. (2001) Two further British families with the 'cryohydrocytosis' form of hereditary stomatocytosis. *British Journal of Haematology*, **113**, 932–937.
- Hassoun, H., Vassiliadis, J.N., Murray, J., Njolstad, P.R., Rogus, J.J., Ballas, S.K., Schaffer, F., Jarolim, P., Brabec, V. & Palek, J. (1997) Characterization of the underlying molecular defect in hereditary spherocytosis associated with spectrin deficiency. *Blood*, **90**, 398–406.
- Hayag-Barin, J.E., Smith, R.E. & Tucker, F.C., Jr (1998) Hereditary spherocytosis, thrombocytosis, and chronic pulmonary emboli: a case report and review of the literature. *American Journal of Hematology*, **57**, 82–84.
- Hirsh, J. & Dacie, J.V. (1966) Persistent post-splenectomy thrombocytosis and thrombo-embolism: a consequence of continuing anaemia. *British Journal of Haematology*, **12**, 44–53.
- Hoepfer, M.M., Niedermeyer, J., Hoffmeyer, F., Flemming, P. & Fabel, H. (1999) Pulmonary hypertension after splenectomy? *Annals of Internal Medicine*, **130**, 506–509.
- Holcomb, G.W., III (1998) Laparoscopic cholecystectomy. *Seminars of Laparoscopic Surgery*, **5**, 2–8.
- Holdsworth, R.J., Irving, A.D. & Cuschieri, A. (1991) Postsplenectomy sepsis and its mortality rate: actual versus perceived risks. *British Journal of Surgery*, **78**, 1031–1038.
- Iolascon, A., Miraglia del Giudice, E., Perrotta, S., Alloisio, N., Morle, L. & Delaunay, J. (1998) Hereditary spherocytosis: from clinical to molecular defects. *Haematologia*, **83**, 240–257.
- Jarolim, P., Rubin, H.L., Brabec, V. & Palek, J. (1995) Comparison of the ankyrin (AC)n microsatellites in genomic DNA and mRNA reveals absence of one ankyrin mRNA allele in 20% of patients with hereditary spherocytosis. *Blood*, **85**, 3278–3282.
- Jarolim, P., Murray, J.L., Rubin, H.L., Taylor, W.M., Prchal, J.T., Ballas, S.K., Snyder, L.M., Chrobak, L., Melrose, W.D., Brabec, V. & Palek, J. (1996) Characterization of 13 novel band 3 gene defects in hereditary spherocytosis with band 3 deficiency. *Blood*, **88**, 4366–4374.
- Jensson, O., Jonasson, J.L. & Magnusson, S. (1977) Studies on hereditary spherocytosis in Iceland. *Acta Medica Scandinavica*, **201**, 187–195.
- Jugenburg, M., Haddock, G., Freedman, M.H., Ford-Jones, L. & Ein, S.H. (1999) The morbidity and mortality of pediatric splenectomy: does prophylaxis make a difference? *Journal of Pediatric Surgery*, **34**, 1064–1067.
- Keenan, R.D., Boswell, T. & Milligan, D.W. (1999) Do post-splenectomy patients take their penicillin. *British Journal of Haematology*, **105**, 509–510.
- Kelleher, J.F., Luban, N.L., Mortimer, P.P. & Kamimura, T. (1983) Human serum 'parvovirus': a specific cause of aplastic crisis in children with hereditary spherocytosis. *Journal of Pediatrics*, **102**, 720–722.
- Kerr, R., Rawlinson, T.S. & Cacia, P.G. (2000) Direct antiglobulin test negative, non-spherocytic autoimmune haemolytic anaemia. *Clinical and Laboratory Haematology*, **22**, 365–367.
- King, M.J., Behrens, J., Rogers, C., Flynn, C., Greenwood, D. & Chambers, K. (2000) Rapid flow cytometric test for the diagnosis of membrane cytoskeleton-associated haemolytic anaemia. *British Journal of Haematology*, **111**, 924–933.
- King, M.-J., Chapman, L., Mackinnon, H., Mills, W., Psiachou-Leonard, E. & Murrin, R. (2003) Examination of flow cytometric histograms of eosin-5-maleimide labelled red cells can assist in differential diagnosis of membranopathy. *British Journal of Haematology*, **121**(Suppl. 1), 75.
- King, M.-J., Smythe, J. & Mushens, R. (2004) Eosin-5-maleimide binding to band 3 and Rh-related proteins forms the basis of a screening test for hereditary spherocytosis. *British Journal of Haematology*, **124**, 106–113.
- Kohler, H., Meynell, M. & Cooke, W. (1960) Spherocytic anaemia complicated by megaloblastic anaemia of pregnancy. *British Medical Journal*, **1**, 779–781.
- Konradsen, H.B. & Henriksen, J. (1991) Pneumococcal infections in splenectomized children are preventable. *Acta Paediatrica Scandinavica*, **80**, 423–427.
- Korones, D. & Pearson, H.A. (1989) Normal erythrocyte osmotic fragility in hereditary spherocytosis. *Journal of Pediatrics*, **114**, 264–266.

- Lefrere, J.J., Courouce, A.M., Girot, R., Bertrand, Y. & Soulier, J.P. (1986) Six cases of hereditary spherocytosis revealed by human parvovirus infection. *British Journal of Haematology*, **62**, 653–658.
- Lindenbaum, J. & Klipstein, F.A. (1963) Folic acid deficiency in sickle-cell anemia. *New England Journal of Medicine*, **269**, 875–882.
- Mackenzie, F., Elliot, D., Eastcott, H., Hughes-Jones, N., Barkhan, P. & Mollinson, P. (1962) Relapse in hereditary spherocytosis with proven splenunculus. *Lancet*, **1**, 1102–1104.
- Marchetti, M., Quaglini, S. & Barosi, G. (1998) Prophylactic splenectomy and cholecystectomy in mild hereditary spherocytosis: analyzing the decision in different clinical scenarios. *Journal of Internal Medicine*, **244**, 217–226.
- McLane, N.J., Grizzard, W.S., Kousseff, B.G., Hartmann, R.C. & Sever, R.J. (1984) Angioid streaks associated with hereditary spherocytosis. *American Journal of Ophthalmology*, **97**, 444–449.
- Michaels, L.A., Cohen, A.R., Zhao, H., Raphael, R.I. & Manno, C.S. (1997) Screening for hereditary spherocytosis by use of automated erythrocyte indexes. *Journal of Pediatrics*, **130**, 957–960.
- Miraglia del Giudice, E., Iolascon, A., Pinto, L., Nobili, B. & Perrotta, S. (1994) Erythrocyte membrane protein alterations underlying clinical heterogeneity in hereditary spherocytosis. *British Journal of Haematology*, **88**, 52–55.
- Miraglia del Giudice, E., Lombardi, C., Francese, M., Nobili, B., Conte, M.L., Amendola, G., Cutillo, S., Iolascon, A. & Perrotta, S. (1998) Frequent de novo monoallelic expression of beta-spectrin gene (SPTB) in children with hereditary spherocytosis and isolated spectrin deficiency. *British Journal of Haematology*, **101**, 251–254.
- Miraglia del Giudice, E., Perrotta, S., Nobili, B., Specchia, C., d'Urzo, G. & Iolascon, A. (1999) Coinheritance of Gilbert syndrome increases the risk for developing gallstones in patients with hereditary spherocytosis. *Blood*, **94**, 2259–2262.
- Miraglia del Giudice, E., Nobili, B., Francese, M., D'Urso, L., Iolascon, A., Eber, S. & Perrotta, S. (2001) Clinical and molecular evaluation of non-dominant hereditary spherocytosis. *British Journal of Haematology*, **112**, 42–47.
- Mohandas, N., Clark, M.R., Jacobs, M.S. & Shohet, S.B. (1980) Analysis of factors regulating erythrocyte deformability. *Journal of Clinical Investigation*, **66**, 563–573.
- Mohandas, N., Kim, Y.R., Tycko, D.H., Orlik, J., Wyatt, J. & Groner, W. (1986) Accurate and independent measurement of volume and hemoglobin concentration of individual red cells by laser light scattering. *Blood*, **68**, 506–513.
- Morton, N., MacKinney, A., Kosowe, N., Schilling, R. & Gray, M. (1962) Genetics of spherocytosis. *American Journal of Human Genetics*, **14**, 170–184.
- Mulder, H., Schlangen, J.T. & van Voorthuisen, A.E. (1975) Extramedullary hematopoiesis in the posterior mediastinum. *Radiology Clinics (Basel)*, **44**, 550–556.
- Nikol, S., Huehns, T.Y., Kiefmann, R. & Hofling, B. (1997) Excessive arterial thrombus in spherocytosis. A case report. *Angiology*, **48**, 743–748.
- Pajor, A., Lehoczy, D. & Szakacs, Z. (1993) Pregnancy and hereditary spherocytosis. Report of 8 patients and a review. *Archives of Gynecology and Obstetrics*, **253**, 37–42.
- Palek, J. & Sahr, K.E. (1992) Mutations of the red blood cell membrane proteins: from clinical evaluation to detection of the underlying genetic defect. *Blood*, **80**, 308–330.
- Parpart, A.K., Lorenz, P.B., Parpart, E.R., Gregg, J.R. & Chase, A.M. (1947) The osmotic resistance (fragility) of human red cells. *Journal of Clinical Investigation*, **26**, 636–640.
- Pati, A.R., Patton, W.N. & Harris, R.I. (1989) The use of the technicon H1 in the diagnosis of hereditary spherocytosis. *Clinical and Laboratory Haematology*, **11**, 27–30.
- Pedersen, F.K. (1983) Postsplenectomy infections in Danish children splenectomized 1969–1978. *Acta Paediatrica Scandinavica*, **72**, 589–595.
- Petit, J.J. & Estany, C. (1987) Mediastinal extramedullary erythropoiesis in hereditary spherocytosis. *Clinical and Laboratory Haematology*, **9**, 327–332.
- Pilar Ricard, M. & Gilanz, F. (1996) Assessment of the severity of hereditary spherocytosis using routine haematological data obtained with dual angle laser scattering cytometry. *Clinical and Laboratory Haematology*, **18**, 75–78.
- Pinto, L., Iolascon, A., Miraglia del Giudice, E., Matarese, S.M.R., Nobili, B. & Perrotta, S. (1995) The Italian survey on hereditary spherocytosis. *International Journal of Pediatric Hematology and Oncology*, **2**, 43–47.
- Pulsoni, A., Ferrazza, G., Malagnino, F., Maurillo, L., Pescarmona, E., Picardi, A., Rendina, E.A. & Amadori, S. (1992) Mediastinal extramedullary hematopoiesis as first manifestation of hereditary spherocytosis. *Annals of Hematology*, **65**, 196–198.
- Reid, M.M. (1994) Splenectomy, sepsis, immunisation, and guidelines. *Lancet*, **344**, 970–971.
- Reinhart, W.H., Wyss, E.J., Arnold, D. & Ott, P. (1994) Hereditary spherocytosis associated with protein band 3 defect in a Swiss kindred. *British Journal of Haematology*, **86**, 147–155.
- Reliene, R., Mariani, M., Zanella, A., Reinhart, W.H., Ribeiro, M.L., del Giudice, E.M., Perrotta, S., Iolascon, A., Eber, S. & Lutz, H.U. (2002) Splenectomy prolongs in vivo survival of erythrocytes differently in spectrin/ankyrin- and band 3-deficient hereditary spherocytosis. *Blood*, **100**, 2208–2215.
- Rescorla, F.J. & Grosfeld, J.L. (1992) Cholecystitis and cholelithiasis in children. *Seminars of Pediatric Surgery*, **1**, 98–106.
- Rescorla, F.J., Engum, S.A., West, K.W., Tres Scherer, L.R., III, Rouse, T.M. & Grosfeld, J.L. (2002) Laparoscopic splenectomy has become the gold standard in children. *American Surgery*, **68**, 297–301; discussion 301–302.
- Rice, H.E., Oldham, K.T., Hillery, C.A., Skinner, M.A., O'Hara, S.M. & Ware, R.E. (2003) Clinical and hematologic benefits of partial splenectomy for congenital hemolytic anemias in children. *Annals of Surgery*, **237**, 281–288.
- Robertson, J.F., Carachi, R., Sweet, E.M. & Raine, P.A. (1988) Cholelithiasis in childhood: a follow-up study. *Journal of Pediatric Surgery*, **23**, 246–249.
- Rosenblatt, D.S. & Hoffbrand, A.V. (1999) Megaloblastic anemia and disorders of cobalamin and folate metabolism. In: *Pediatric Hematology* (ed. by J.S. Lilleyman, I.M. Hann & V.S. Blanchette), pp. 167–184. Churchill Livingstone, London.
- Rutkow, I.M. (1981) Twenty years of splenectomy for hereditary spherocytosis. *Archives of Surgery*, **116**, 306–308.
- Rybicki, A.C., Schwartz, R.S., Hustedt, E.J. & Cobb, C.E. (1996) Increased rotational mobility and extractability of band 3 from protein 4.2-deficient erythrocyte membranes: evidence of a role for protein 4.2 in strengthening the band 3-cytoskeleton linkage. *Blood*, **88**, 2745–2753.

- Sandler, A., Winkel, G., Kimura, K. & Soper, R. (1999) The role of prophylactic cholecystectomy during splenectomy in children with hereditary spherocytosis. *Journal of Pediatric Surgery*, **34**, 1077–1078.
- Schroter, W. & Kahsnitz, E. (1983) Diagnosis of hereditary spherocytosis in newborn infants. *Journal of Pediatrics*, **103**, 460–463.
- Smith, B.M., Schropp, K.P., Lobe, T.E., Rogers, D.A., Presbury, G.J., Wilimas, J.A. & Wong, W.C. (1994) Laparoscopic splenectomy in childhood. *Journal of Pediatric Surgery*, **29**, 975–977.
- Spickett, G.P., Bullimore, J., Wallis, J., Smith, S. & Saunders, P. (1999) Northern Region asplenia register – analysis of first two years. *Journal of Clinical Pathology*, **52**, 424–429.
- Stenson, P.D., Ball, E.V., Mort, M., Phillips, A.D., Shiel, J.A., Thomas, N.S., Abeysinghe, S., Krawczak, M. & Cooper, D.N. (2003) Human Gene Mutation Database (HGMD): 2003 update. *Human Mutation*, **21**, 577–581.
- Stewart, G.W. & Turner, E.J. (1999) The hereditary stomatocytoses and allied disorders: congenital disorders of erythrocyte membrane permeability to Na and K. *Baillieres Best Practice and Research Clinical Haematology*, **12**, 707–727.
- Stewart, G.W., Amess, J.A., Eber, S.W., Kingswood, C., Lane, P.A., Smith, B.D. & Mentzer, W.C. (1996) Thrombo-embolic disease after splenectomy for hereditary stomatocytosis. *British Journal of Haematology*, **93**, 303–310.
- Streichman, S. & Gescheidt, Y. (1998) Cryohemolysis for the detection of hereditary spherocytosis: correlation studies with osmotic fragility and autohemolysis. *American Journal of Hematology*, **58**, 206–212.
- Summerfield, G.P. & Wyatt, G.P. (1985) Human parvovirus infection revealing hereditary spherocytosis. *Lancet*, **2**, 1070.
- Sutton, C.D., Garcea, G., Marshall, L.J., Lloyd, T.D., De Alwis, C. & Lewis, M.H. (2003) Pelvic extramedullary haematopoiesis associated with hereditary spherocytosis. *European Journal of Haematology*, **70**, 326–329.
- Tanoue, K., Okita, K., Akahoshi, T., Konishi, K., Gotoh, N., Tsutsumi, N., Tomikawa, M. & Hashizume, M. (2002) Laparoscopic splenectomy for hematologic diseases. *Surgery*, **131**, S318–S323.
- Tchernia, G., Gauthier, F., Mielot, F., Dommergues, J.P., Yvart, J., Chasis, J.A. & Mohandas, N. (1993) Initial assessment of the beneficial effect of partial splenectomy in hereditary spherocytosis. *Blood*, **81**, 2014–2020.
- Tchernia, G., Bader-Meunier, B., Berterottiere, P., Eber, S., Dommergues, J.P. & Gauthier, F. (1997) Effectiveness of partial splenectomy in hereditary spherocytosis. *Current Opinion in Hematology*, **4**, 136–141.
- Tchernia, G., Delhommeau, F., Perrotta, S., Cynober, T., Bader-Meunier, B., Nobili, B., Rohrllich, P., Salomon, J.L., Sagot-Bevenot, S., del Giudice, E.M., Delaunay, J., DeMattia, D., Schischmanoff, P.O., Mohandas, N. & Iolascon, A. (2000) Recombinant erythropoietin therapy as an alternative to blood transfusions in infants with hereditary spherocytosis. *Hematology Journal*, **1**, 146–152.
- Tse, W.T. & Lux, S.E. (1999) Red blood cell membrane disorders. *British Journal of Haematology*, **104**, 2–13.
- Waghorn, D. & Mayon-White, R. (1997) A study of 42 episodes of overwhelming post-splenectomy infection: is guidance for asplenic individuals being followed? *Journal of Infection*, **35**, 289–294.
- Walker, W. (1976) Splenectomy in childhood; a review in England and Wales. *British Journal of Surgery*, **63**, 36–43.
- Wandersee, N.J., Lee, J.C., Deveau, S.A. & Barker, J.E. (2001) Reduced incidence of thrombosis in mice with hereditary spherocytosis following neonatal treatment with normal hematopoietic cells. *Blood*, **97**, 3972–3975.
- Whitfield, C.F., Follweiler, J.B., Lopresti-Morrow, L. & Miller, B.A. (1991) Deficiency of alpha-spectrin synthesis in burst-forming units-erythroid in lethal hereditary spherocytosis. *Blood*, **78**, 3043–3051.
- Wichterle, H., Hanspal, M., Palek, J. & Jarolim, P. (1996) Combination of two mutant alpha spectrin alleles underlies a severe spherocytic hemolytic anemia. *Journal of Clinical Investigation*, **98**, 2300–2307.
- Wolfe, L.C., John, K.M., Falcone, J.C., Byrne, A.M. & Lux, S.E. (1982) A genetic defect in the binding of protein 4.1 to spectrin in a kindred with hereditary spherocytosis. *New England Journal of Medicine*, **307**, 1367–1374.
- Xiros, N., Economopoulos, T., Papageorgiou, E., Mantzios, G. & Raptis, S. (2001) Massive hemothorax due to intrathoracic extramedullary hematopoiesis in a patient with hereditary spherocytosis. *Annals of Hematology*, **80**, 38–40.
- Yawata, Y., Kanzaki, A., Inoue, T., Ata, K., Wada, H., Okamoto, N., Higo, I., Yawata, A., Sugihara, T. & Yamada, O. (1994) Red cell membrane disorders in the Japanese population: clinical, biochemical, electron microscopic, and genetic studies. *International Journal of Hematology*, **60**, 23–38.
- Zanella, A., Izzo, C., Rebulli, P., Zanuso, F., Perroni, L. & Sirchia, G. (1980) Acidified glycerol lysis test: a screening test for spherocytosis. *British Journal of Haematology*, **45**, 481–486.

Appendix

The definitions of the types of evidence and the grading recommendations used in this guideline originate from the US Agency for Health Care Policy and Research and are set out below.

Statements of evidence

- Ia** Evidence obtained from the meta-analysis of randomized controlled trials.
- Ib** Evidence obtained from at least one randomized controlled trial.
- IIa** Evidence obtained from at least one well-designed controlled study without randomization.
- IIb** Evidence obtained from at least one other type of well-designed quasi-experimental study.
- III** Evidence obtained from well-designed non-experimental descriptive studies, such as comparative studies, correlation studies and case studies.
- IV** Evidence obtained from expert committee reports or opinions and/or clinical experiences of respected authorities.

Grades of recommendations

- A** Required at least one randomized controlled trial as part of a body literature of overall good quality and consistency addressing the specific recommendations (evidence levels Ia, Ib).

Guideline

- B** Requires the available of well conducted clinical studies but no randomized clinical trials on the topic of recommendations (evidence levels IIa, IIb, III).
- C** Requires evidence obtained from expert committee reports or opinions and/or clinical experiences of respected authorities. Indicates an absence of directly applicable clinical studies of good quality (evidence level IV).